

A collection of medical supplies including a stethoscope, a digital thermometer, a pencil, a bandage, and various pills and capsules, all arranged on a teal background.

# African Journal of Pharmacy and Pharmacology

Volume 10 Number 2, 15 January, 2016  
ISSN 1996-0816

**MEDICAL**



## ABOUT AJPP

The **African Journal of Pharmacy and Pharmacology (AJPP)** is published weekly (one volume per year) by Academic Journals.

**African Journal of Pharmacy and Pharmacology (AJPP)** is an open access journal that provides rapid publication (weekly) of articles in all areas of Pharmaceutical Science such as Pharmaceutical Microbiology, Pharmaceutical Raw Material Science, Formulations, Molecular modeling, Health sector Reforms, Drug Delivery, Pharmacokinetics and Pharmacodynamics, Pharmacognosy, Social and Administrative Pharmacy, Pharmaceutics and Pharmaceutical Microbiology, Herbal Medicines research, Pharmaceutical Raw Materials development/utilization, Novel drug delivery systems, Polymer/Cosmetic Science, Food/Drug Interaction, Herbal drugs evaluation, Physical Pharmaceutics, Medication management, Cosmetic Science, pharmaceuticals, pharmacology, pharmaceutical research etc. The Journal welcomes the submission of manuscripts that meet the general criteria of significance and scientific excellence. Papers will be published shortly after acceptance. All articles published in AJPP are peer-reviewed.

### Contact Us

Editorial Office: [ajpp@academicjournals.org](mailto:ajpp@academicjournals.org)

Help Desk: [helpdesk@academicjournals.org](mailto:helpdesk@academicjournals.org)

Website: <http://www.academicjournals.org/journal/AJPP>

Submit manuscript online <http://ms.academicjournals.me/>

## Editors

### **Sharmilah Pamela Seetulsingh- Goorah**

*Associate Professor,  
Department of Health Sciences  
Faculty of Science,  
University of Mauritius,  
Reduit,  
Mauritius*

### **Himanshu Gupta**

*University of Colorado- Anschutz Medical Campus,  
Department of Pharmaceutical Sciences, School of  
Pharmacy Aurora, CO 80045,  
USA*

### **Dr. Shreesh Kumar Ojha**

*Molecular Cardiovascular Research Program  
College of Medicine  
Arizona Health Sciences Center  
University of Arizona  
Tucson 85719, Arizona,  
USA*

### **Dr.Victor Valenti Engracia**

*Department of Speech-Language and  
Hearing Therapy Faculty of Philosophy  
and Sciences, UNESP  
Marilia-SP, Brazil.*

### **Prof. Sutiak Vaclav**

*Rovníková 7, 040 20 Košice,  
The Slovak Republic,  
The Central Europe,  
European Union  
Slovak Republic  
Slovakia*

### **Dr.B.RAVISHANKAR**

*Director and Professor of Experimental Medicine  
SDM Centre for Ayurveda and Allied Sciences,  
SDM College of Ayurveda Campus,  
Kuthpady, Udupi- 574118  
Karnataka (INDIA)*

### **Dr. Manal Moustafa Zaki**

*Department of Veterinary Hygiene and Management  
Faculty of Veterinary Medicine, Cairo University  
Giza, 11221 Egypt*

### **Prof. George G. Nomikos**

*Scientific Medical Director  
Clinical Science  
Neuroscience  
TAKEDA GLOBAL RESEARCH & DEVELOPMENT  
CENTER, INC. 675 North Field Drive Lake Forest, IL  
60045  
USA*

### **Prof. Mahmoud Mohamed El-Mas**

*Department of Pharmacology,*

### **Dr. Caroline Wagner**

*Universidade Federal do Pampa  
Avenida Pedro Anunciação, s/n  
Vila Batista, Caçapava do Sul, RS - Brazil*

## Editorial Board

**Prof. Fen Jicai**

*School of life science, Xinjiang University, China.*

**Dr. Ana Laura Nicoletti Carvalho**

*Av. Dr. Arnaldo, 455, São Paulo, SP. Brazil.*

**Dr. Ming-hui Zhao**

*Professor of Medicine  
Director of Renal Division, Department of Medicine  
Peking University First Hospital  
Beijing 100034  
PR. China.*

**Prof. Ji Junjun**

*Guangdong Cardiovascular Institute, Guangdong General Hospital, Guangdong Academy of Medical Sciences, China.*

**Prof. Yan Zhang**

*Faculty of Engineering and Applied Science,  
Memorial University of Newfoundland,  
Canada.*

**Dr. Naoufel Madani**

*Medical Intensive Care Unit  
University hospital Ibn Sina, Univesity Mohamed V  
Souissi, Rabat,  
Morocco.*

**Dr. Dong Hui**

*Department of Gynaecology and Obstetrics, the 1st hospital, NanFang University, China.*

**Prof. Ma Hui**

*School of Medicine, Lanzhou University, China.*

**Prof. Gu HuiJun**

*School of Medicine, Taizhou university, China.*

**Dr. Chan Kim Wei**

*Research Officer  
Laboratory of Molecular Biomedicine,  
Institute of Bioscience, Universiti Putra,  
Malaysia.*

**Dr. Fen Cun**

*Professor, Department of Pharmacology, Xinjiang University, China.*

**Dr. Sirajunnisa Razack**

*Department of Chemical Engineering, Annamalai University, Annamalai Nagar, Tamilnadu, India.*

**Prof. Ehab S. EL Desoky**

*Professor of pharmacology, Faculty of Medicine Assiut University, Assiut, Egypt.*

**Dr. Yakisich, J. Sebastian**

*Assistant Professor, Department of Clinical Neuroscience R54  
Karolinska University Hospital, Huddinge  
141 86 Stockholm ,  
Sweden.*

**Prof. Dr. Andrei N. Tchernitchin**

*Head, Laboratory of Experimental Endocrinology and Environmental Pathology LEEPA  
University of Chile Medical School,  
Chile.*

**Dr. Sirajunnisa Razack**

*Department of Chemical Engineering,  
Annamalai University, Annamalai Nagar, Tamilnadu, India.*

**Dr. Yasar Tatar**

*Marmara University,  
Turkey.*

**Dr Nafisa Hassan Ali**

*Assistant Professor, Dow institute of medical technology  
Dow University of Health Sciences, Chand bbi Road, Karachi,  
Pakistan.*

**Dr. Krishnan Namboori P. K.**

*Computational Chemistry Group, Computational Engineering and Networking,  
Amrita Vishwa Vidyapeetham, Amritanagar, Coimbatore-641 112  
India.*

**Prof. Osman Ghani**

*University of Sargodha,  
Pakistan.*

**Dr. Liu Xiaoji**

*School of Medicine, Shihezi University,  
China.*

**ARTICLE**

**Susceptibility of *Blastocystis hominis* to monolaurine (Lauric acid), lactoferine (*Lactobacillus acidophillus*) and metronidazole: An in vitro and in vivo studies**

**14**

Soad Ismail, Iman Ali, Neimat Amer, Zeinab Fahmy, Magda Azmy and Mona Magdy

## Full Length Research Paper

## Susceptibility of *Blastocystis hominis* to monolaurine (Lauric acid), lactoferine (*Lactobacillus acidophillus*) and metronidazole: An *in vitro* and *in vivo* studies

Soad Ismail<sup>1</sup>, Iman Ali<sup>1</sup>, Neimat Amer<sup>1\*</sup>, Zeinab Fahmy<sup>1</sup>, Magda Azmy<sup>2</sup> and Mona Magdy<sup>3</sup><sup>1</sup>Department of Parasitology, Theodor Bilharz Research Institute. P. O. Box 30, Imbaba, Cairo, Egypt.<sup>2</sup>Department of Electron Microscope, Theodor Bilharz Research Institute. P. O. Box 30, Imbaba, Cairo, Egypt.<sup>3</sup>Department of Pathology, Theodor Bilharz Research Institute. P. O. Box 30, Imbaba, Cairo, Egypt.

Received 30 May, 2015; Accepted 21 October, 2015

***Blastocystis hominis* is an unusual enteric protozoan of human and animals. Natural products are not only the basis for traditional or ethnic medicine, but also provides highly successful new regimen for human welfare. Meronidazole constitutes a mainstay and is also traditionally considered first line therapy for treatment of Blastocystosis. However, the therapy is complicated due to different dosages and regimens adopted and the unresponsiveness to all treatment. A lot of interest has been generated on the role of probiotic, coconut oil and its fatty acid (Lauric acid) on eradication of the parasite. This study, appraised the effect of monolaurine, lactoferine and metronidazole using different dose regimens on experimental Blastocystosis. Assessment of evaluation was performed by determining the number of oocysts/gm stool, number of vegetative forms and histopathological changes in the intestine, in addition to *in vitro* susceptibility and ultrastructural changes of *B. hominis* following incubation with the previous agents. Each hamster was infected orally by 10.000 oocysts. Three weeks later, animals were divided into 6 groups, a control group and five other groups according to the drug they received. Drugs were taken for 5 consecutive days. Two weeks later, scarification of animals was performed and occyst/gm stool and trophozoites in the intestine were counted. *In vitro* incubation of the parasite with Lactoferine (1000 and 2000 µg/ml), metronidazole (120 and 200 µg/ml) was counted at different time periods (1/2, 1 and 2 h). Parasite viability was assessed using eosin-brilliant cresyle blue exclusion test. Ultrastructural changes of *B. hominis* following incubation of drugs were studied using transmission electron microscope. This study adds to the fact that natural products can offer an alternative therapy to be used in place of or concurrently with conventional antimicrobials.**

**Key words:** *Blastocystis hominis*, lactoferine, monolaurin, metronidazole transmission electron microscope, *in vitro* cultivation, histopathology.

### INTRODUCTION

*Blastocystis hominis* is a unicellular, genetically diverse protist, phylogenetically placed within the stramenopiles

(Scanlan, 2012). It is the only member of this group associated with human pathological changes (Tan, 2008;

\*Corresponding author. E-mail: amerneimat@gmail.com.

Tan et al., 2010). It has a worldwide distribution, and is considered the most commonly isolated organism (0.8 to 61.8%) in parasitological surveys (Jenkins et al., 2005). *B. hominis* is a species complex comprising 17 subtypes (STs) at least 9 of which are found in humans (Poirier et al., 2012; Alfellani et al., 2013). The prevalence of this parasite is usually higher in developing countries, ranging from 30 to 50%, in developing countries and 1.5 to 15% in developed countries (Tan, 2008; Kulik et al., 2008). However, some selected populations in developed countries may have much higher prevalence (Parkar et al., 2007). It is frequently reported in human fecal samples from symptomatic patients as well as healthy individuals. The parasite induces enteritis, manifested in mucous and watery diarrhea, bloating, abdominal pain and/or vomiting (Tan et al., 2010). Clinical studies also associate *Blastocystis* with other intestinal and dermatological inflammatory disorders, such as irritable bowel syndrome and urticaria, respectively. Patients immune compromised due to the human immunodeficiency virus (HIV) or cancer are particularly susceptible to infections, suggesting that *Blastocystis* is also an opportunistic pathogen (Kumiawan et al., 2009; Tasova et al., 2000).

Medicinal plants have been used commonly in developing countries due to their availability, inexpensiveness and traditional use for centuries. Due to the controversy surrounding the potential pathogenicity of *Blastocystis* and the self-limiting nature of symptoms, the treatment of this disease is equivocal. Metronidazole is the most frequently prescribed antibiotic for infections (Mirza and Tan, 2012). Nitazoxanide, a broad-spectrum 5-nitrothiazole antiparasitic agent has also been reported to be effective in treatment (Diaz et al., 2003; Rossignol et al., 2005). A case study in Australia of 18 patients showed that clearance of *Blastocystis* and symptoms did not occur after treatment with either metronidazole, iodoquinol or triple combination therapy consisting of nitazoxanide, furazolidone and secnidazole showing the lack of efficacy of several commonly used antimicrobials for the treatment of *Blastocystis* (Sekar and Shanthe, 2013).

Treatment should be considered if there are chronic symptoms of diarrhea and abdominal pain in the absence of other pathogens identified from the stool sample. Metronidazole should not necessarily be considered first line treatment due to the large number of cases of treatment failure. There may be a correlation between subtypes and sensitivity to drugs which is yet to be addressed in studies (Kelesidis and Pothoulakis, 2012). Several clinical trials and experimental studies strongly suggest a place for probiotics as a biotherapeutic agent for the prevention and treatment of several gastrointestinal diseases. Probiotics mediates responses resembling the protective effects of the normal healthy gut flora. The multiple mechanisms of action of probiotics and its properties may explain its efficacy and beneficial

effects in acute and chronic gastrointestinal diseases that have been confirmed by clinical trials (Kelesidis and Pothoulakis, 2012).

Lactobacillus seems to have a beneficial effect in amebiasis, giardiasis and infection with *Blastocystis hominis*. A lot of interest has also been generated on the role of probiotics particularly *Saccharomyces boulardii* and other natural food compounds on eradication of the parasite (Choi et al., 2011). Much of the recent research done on coconut oil and *lauric acid*, the most predominant fatty acid chain found in coconut oil, has centered around the antimicrobial and anti-viral properties of this unique fatty acid. When *lauric acid* is consumed in the diet, *lauric acid* forms a monoglyceride called monolaurin, which has been shown to destroy several bacteria and viruses, including listeria monocytogenes and *Helicobacter pylori*, and protozoa such as *Giardia lamblia*.

This study highlights the need to reevaluate established treatment for *Blastocystis* infection and offers clear view treatment options for Metronidazole failures.

## MATERIALS AND METHODS

This study was carried out in the Parasitology, Pathology and Electron Microscopic Departments in Theodor Bilharz Research Institute (TBRI). All experimental animal studies were managed in accordance with the international guidelines.

### Experimental animals

*In-vivo* studies were carried out in both parasitology and pathology departments. Thirty laboratory bred Syrian hamsters (*Mesocricetus auratus*) weighing 100 to 110 gms, were provided by the schistosome Biological Supply Program in TBRI.

### Experimental design

Out of these 30 hamsters, 5 served as infected non-treated control. Five hamsters received metronidazole (200 µg/ml). Five hamsters received lausic acid (2000 µg/ml). Five hamsters received monolaurine (2000 µg/ml). Five hamsters received 1/3 dose of metronidazole + 2/3 dose of monolaurine, and finally the last group received 1/3 dose metronidazole 2/3 dose of lactobacillus. All groups except the first group received the above mentioned drugs for 5 consecutive days.

### Parasites

Fresh stool samples were obtained from patients attending parasitology lab. in outpatient clinic of TBRI. Stool samples were examined by wet smear (Melvin, 1974), MIFC technique (Melvin and Brooke, 1974) and Giemsa stain, (Blagg et al., 1955).

### Infection

Stool samples were repeatedly sieved and washed using normal saline. Each animal was infected by 10,000 *Blastocystis* oocyst orally. Three weeks following infection, treatment was given.

## Drugs

- (i) metronidazole: A standard drug supplied by Rhone Poulenc Rorer given in a dose of 200 µg/ml.  
 (ii) Monolaurine: A food supplement manufactured by Ecological formulas (Med. Chemical lab. Denmark, suspended in 10% DMSO. (Dose, 2000 µg/ml).  
 (iii) Lactobacillus acidophilus: Obtained from Egyptian Ministry of Health and Population License no. 23922 RAMEDA Axcan Pharma (Dose 2000 µg/ml). Two weeks following treatment, sacrifice of animals was performed and oocysts/gram stools and trophozoites in the intestine were counted.  
*In-vitro* study was carried out in the Parasitology and Electron Microscopic Departments in TBRI.

## Parasites

Fresh stool samples were obtained from patients attending parasitology laboratory in outpatient clinic of TBRI. Stool samples were examined by wet smear (Zierdt, 1991), merthiolate iodine formaldehyde concentration (MIFC) technique (Zierdt et al., 1988) and giemsa stain (Tan, 2008).

## Drugs

- Concentration of parasite cells/ml of culture was determined after incubation with different concentrations of drugs at different time intervals". (1/2, 1 and 2 h).  
 (i) Metronidazole: Supplied by Rhone Poulenc Rorer (concentration: 120 and 200 µg/ml).  
 (ii) Monolaurine: Manufactured by: Ecological formulas Med. Chemical lab. Denmark (concentration: 1000, 1500 and 2000 µg/ml).  
 (iii) Lactobacillus acidophilus: Obtained from Egyptian Ministry of Health and population License no. 23922 RAMEDA Axcan Pharma, (concentration: 1000 and 2000 µg/ml).  
 (iv) 1% Dimethyl Sulphoxide (DMSO), as a Vehicle Solvent.  
 (v) *In-vitro* cultivation of stool samples positive for *B. hominis*: Approx 50 mg of each fecal sample was inoculated into 2 ml of Locke medium (Fenoglio et al., 2008), supplemented with 20% horse serum in a screw cap tube. Tubes were incubated at 37°C for 48 h and a drop of cultured sol. was examined under the light microscope at x10 and x40 magnifications. *B. hominis* vacuolar forms were found in culture specimens were of variable sizes. Culture was regarded as negative, when it was failed to detect *B. hominis* after 72 h (Grimaud et al., 1980).  
 (vi) Stool culture was undertaken to exclude bacterial pathogens.  
 (vii) All tubes of different groups were incubated in a humidified C<sup>2</sup> at 37°C for ascending time intervals (30 min, 1 and 2 h).  
 (viii) Parasites were counted using a Neubauer haemocytometer (Weber England) and trophozoite viability was assessed using Eosin Brilliant cresyl blue stain.

## Histopathological examination

Small intestine of all mice groups were fixed in 10% buffered formalin and processed to paraffin blocks. Tissue section were cut 250 µm apart from the proceeding sections. Paraffin section was prepared from each animal and stained with Hx and Eosin for histopathological examination (Zierdt, 1988).

## Transmission electron microscopic examination (TEM)

For culture sediment after incubated with different drugs was done

as a trial to discuss the mode of action of these drugs. Samples from different groups were fixed in 4% glutaraldehyde in 0.1 sodium cacodylate buffer to be studied by TEM according to Grimaud et al. (1980). TEM examination was performed in electron microscopy laboratory at TBRI, (Rayan et al., 2007).

## RESULTS

There was a significant difference between all treated groups and the control group. The vegetative forms/field were as follows: control 48.33, metronidazole (200 mg/ml) 37.33, monolaurine (2000 m/ml): 17.33, lactoferine (2000 g/ml): 16.66, metronidazole 1/3 dose + lactoferine 2/3 dose: 7.33. As for the number of oocyst/gm stool, it was found to be: 216, 150, 100, 25, 37.33, 7.66, respectively. Histopathological examination revealed normal villi with no atrophy or inflammation as well as absence of *Blastocystis* in the groups receiving metronidazole, monolaurine and their combination, while in the groups receiving lactoferine alone or combined with metronidazole, few *B. oocysts* still persisted with some foci of inflammation. No viable oocysts were found after 1 h when lactoferine (2000 µg/ml) and monolaurin (2000 µg/ml) were used compared to 15% viability when metronidazole was added (Tables 1 and 2).

Concentration of parasite cell/ml of culture was determined after incubation with different concentration of drugs at different time intervals. The highest concentration of lactoferine (200µg/ml) caused rapid death of the parasite after 1 h. While the highest concentration of monolaurin that caused rapid death was 2000 µg/ml after ½ h. TEM studies of *B. hominis* cells displayed key morphological features of programmed cell death with shrinkage of cytoplasm with metronidazole (200 µg/ml) and shrinking of cell wall after exposure to 2000 µg/ml lactoferine. Histopathological figures are shown in Figures 1 to 7, electron microscopic figures are shown in Figures 8 to 11.

## DISCUSSION

Recent studies have identified potential parasite virulence factors in and host responses to this parasite. Although Metronidazole is the treatment of choice, physicians are often skeptical about prescribing antibiotics for *Blastocystis* infections due to frequent reports of non-responsiveness to chemotherapy. Strain-to-strain variation within *Blastocystis* in susceptibility to metronidazole and other antiparasitic agents among *Blastocystis* strains is commonly reported, and has been proposed to be the reason for frequent treatment failures in parasite infections (Tan, 2008; Mirza and Tan, 2012).

However, from an evolutionary standpoint, mutations associated with drug resistance may impair essential biological functions or impose energy demands on the organism, leading to decreased microbial fitness. Its role in human diseases was widely debated in the literature



**Table 1.** Effect of lactobacillus LB and metronidazole on *blastocystis* cell concentration in culture.

Drug/Concentration ( $\mu\text{g/ml}$ )	Cells/ml (mean $\pm$ SEM) (1/2 h)	Cells/ml (mean $\pm$ SEM) (1 h)	Cells/ml (mean $\pm$ SEM) (2 h)
Control	102x 10 <sup>4</sup> $\pm$ 1.40	102x 10 <sup>4</sup> $\pm$ 1.40	102x 10 <sup>4</sup> $\pm$ 1.40
1% DMSO	100x 10 <sup>4</sup> $\pm$ 4.08	100x 10 <sup>4</sup> $\pm$ 4.08	100x 10 <sup>4</sup> $\pm$ 4.08
Metronidazole 120	46.5x 10 <sup>4</sup> $\pm$ 2.06*+	38.25x 10 <sup>4</sup> $\pm$ 0.85*+	22x 10 <sup>4</sup> $\pm$ 1.22*+
Metronidazole 200	19.5x 10 <sup>4</sup> $\pm$ 1.33*+\$	8.0x 10 <sup>4</sup> $\pm$ 0.44*+\$	-
Lactobacillus 1000	29.4x 10 <sup>4</sup> $\pm$ 0.29*+\$\$%	14.5x 10 <sup>4</sup> $\pm$ 0.91*+\$\$%	6.5x 10 <sup>4</sup> $\pm$ 0.28*+\$\$%
Lactobacillus 2000	15.25x 10 <sup>4</sup> $\pm$ 0.47*+\$\$#	0	0

\*Significant difference between treated group and control groups ( $P<0.05$ ); +Significant difference between treated group and DMSO group ( $P<0.05$ ); \$ Significant difference between treated group and Metronidazole 120 ( $P<0.05$ ); % Significant difference between treated group and Metronidazole 200 ( $P<0.05$ ); # Significant difference between treated group and 1000 (Lacteol) ( $P<0.05$ ).

**Table 2.** The effect of *Monolaurin* (ML) and Lacteol fort (lactobacillus LB) on the number alone or combined, and metronidazole of (trophozoites) intestinal contents and cysts excreted in stool.

Concentration ( $\mu\text{g/ml}$ )	Vegetative forms in intestinal contents/field	Oocysts/gm stool
Infected control (c)	48.33 $\pm$ 4.40	216.6 $\pm$ 8.81
Infected treated with Metronidazole 200	37.33 $\pm$ 1.45*	150 $\pm$ 5.77*
Infected treated with <i>Monolaurin</i> 2000	17.33 $\pm$ 1.45*+	100 $\pm$ 2.30*+
Infected treated with Lactobacillus 2000	16.66 $\pm$ 0.88*	35 $\pm$ 2.88*+\$
Infected treated with Metro (1/3dose)+Monol. (2/3dose)	12.33 $\pm$ 1.45*+%	7.33 $\pm$ 0.88*+\$\$%
Infected treated with Metro (1/3dose)+Lacto. (2/3dose)	7.33 $\pm$ 0.88*+%	7.66 $\pm$ 0.88*+\$\$

\*Significant difference between infected treated groups and control groups ( $P<0.05$ ); + Significant difference between infected treated groups and Metronidazole groups ( $P<0.05$ ); \$ Significant difference between infected treated groups and *Monolaurine* (M) ( $P<0.05$ ); % Significant difference between infected treated groups and (M+F) ( $P<0.05$ ); # Significant difference between infected treated groups and control groups ( $P<0.05$ ).

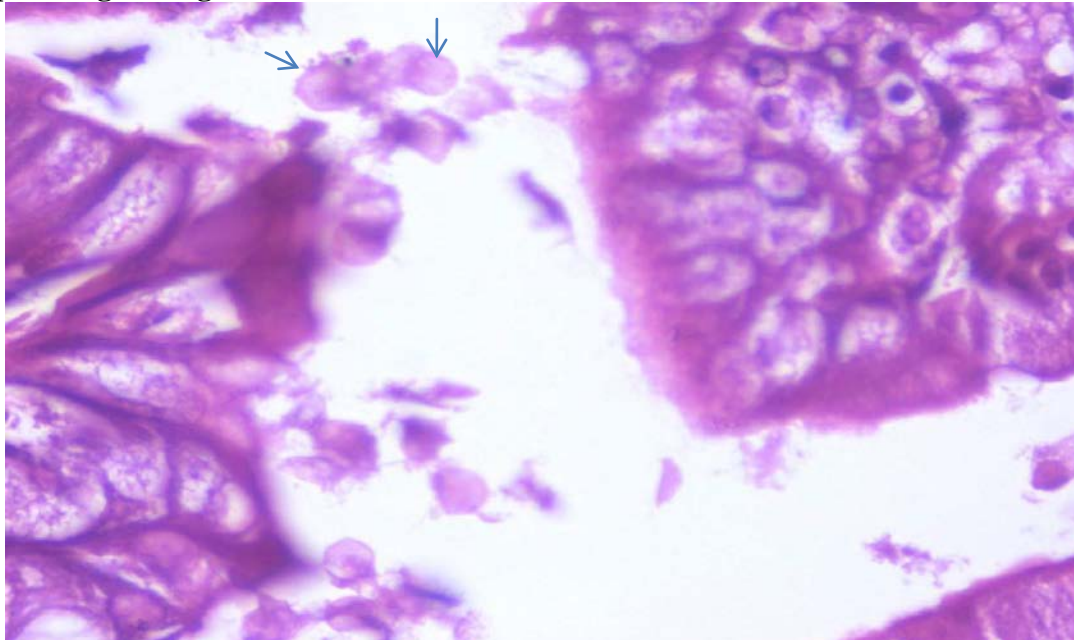
during the last two decades. Numerous recent *in-vivo* and *in-vitro* studies, strongly suggest that *Blastocystis* is a pathogen (John et al., 1997; Boorum et al., 2008). Considering the frequent reports of treatment failure in humans with symptomatic *Blastocystis* infections, it will be interesting to evaluate the effect of natural products on the pathogenicity and response to treatment alone or combined with metronidazole on experimental blastocystosis (Boorum et al., 2008).

In traditional medicine, leaves, bodies, fruits and seeds of many plant species have long been used as anti-diarrheic agents. As medical agents are relatively expensive and may cause significant side effects in patients, herbal compounds are used commonly by local people. Some of these herbal compounds may have significant potential therapeutic effects against different

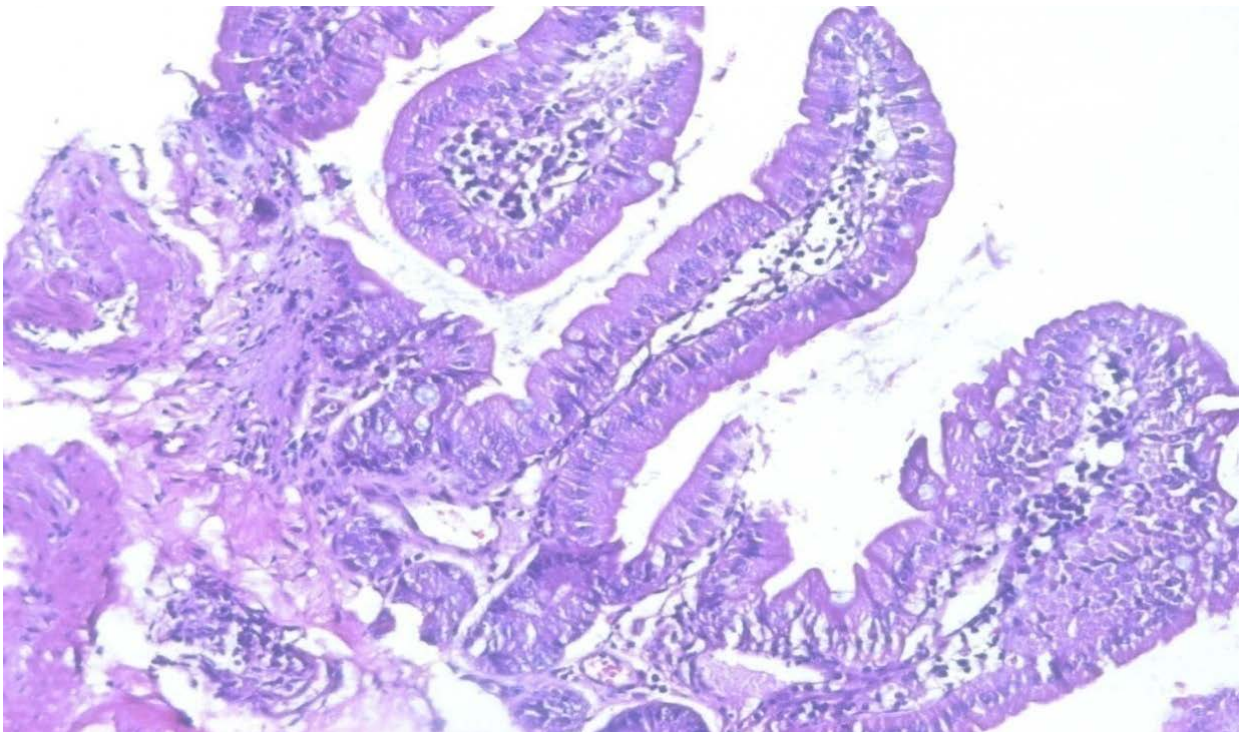
parasites, and may turn out to be registered drugs for these infections in the future (Travers et al., 2011).

The use of probiotics (live viable microbial organisms) in the treatment of specific diseases has evolved into an extremely valuable option, yet to be optimally used in clinical medicine. Probiotics have been shown to have immunomodulating properties and enhance the mucosal barrier. They can have a significant influence on the treatment and prevention of disease. Over 400 different species of micro-organisms reside in the human gastrointestinal tract (GI). Lactobacilli are perhaps the most well known of these favorable micro-organisms (Termmathurapoj et al., 2004; Stenzel and Boreham, 1996).

Culture is recommended to be a routine diagnostic procedure in diagnosis of *Blastocystis*, as it is easy to



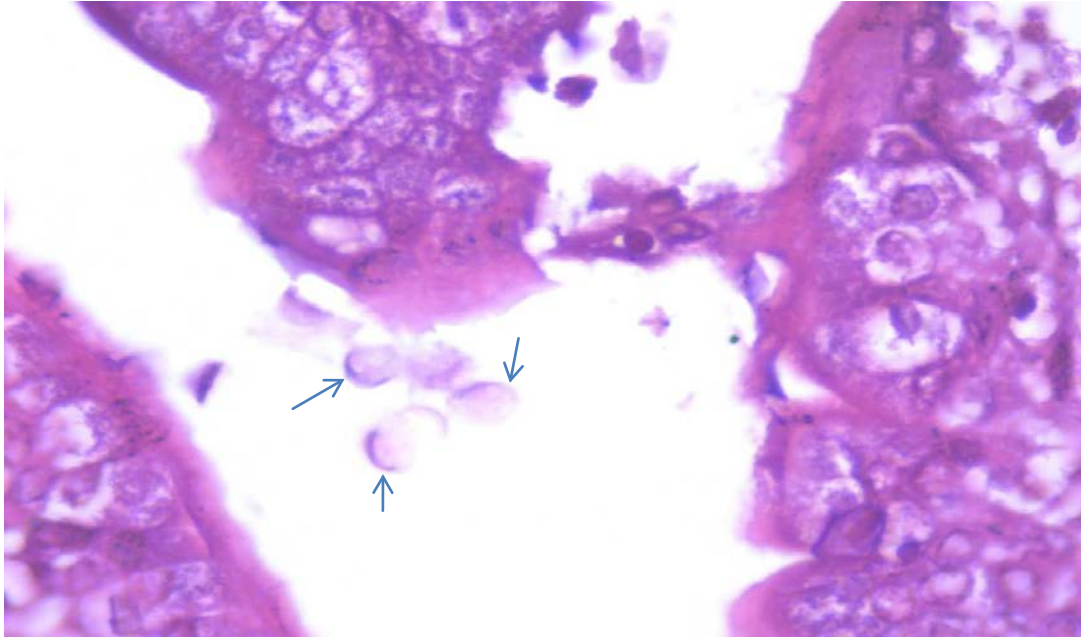
**Figure 1.** Infected control. Plenty of *Blastocystis* forms on the intestinal surface as well as variable degree of villous atrophy and foci of moderate inflammation *Blastocystis* (arrows ). H&Ex1000.



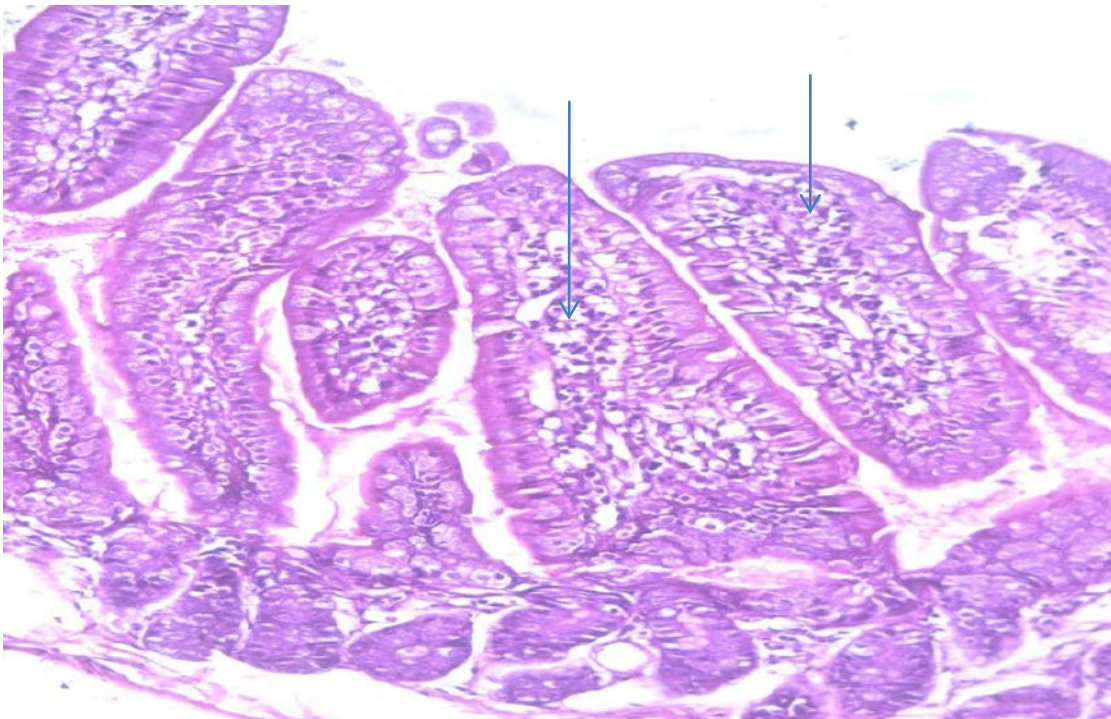
**Figure 2.** Metronidazole treated group. Intestine showing, normal villi with no inflammation and no *Blastocystis* forms (H&Ex200).

prepare and increases the size and number of the organism (Amer et al., 2007). Transmission electron

microscopy (TEM) assist in confirming the diagnosis if atypical morphological forms of *Blastocystis* species are



**Figure 3.** Lactobacillus treated group. Some deformed *Blastocystis* forms at the intestinal surface (arrows) H&Ex1000.

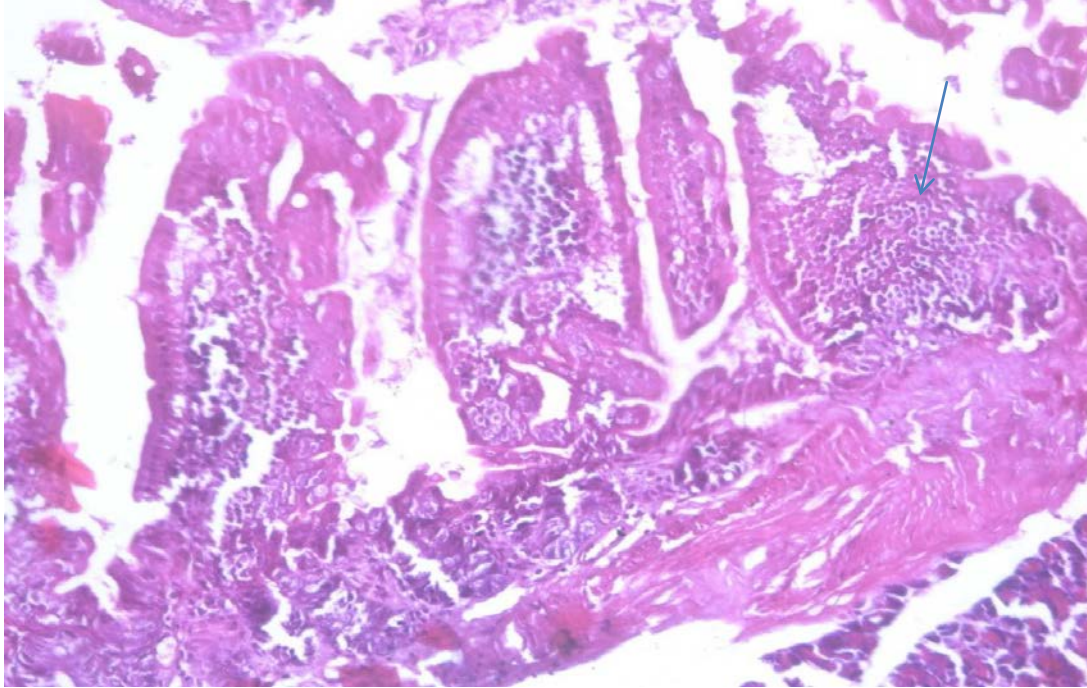


**Figure 4.** Lactobacillus + Metronidazole treated group. Normal villi with mild inflammation (arrows) H&Ex200.

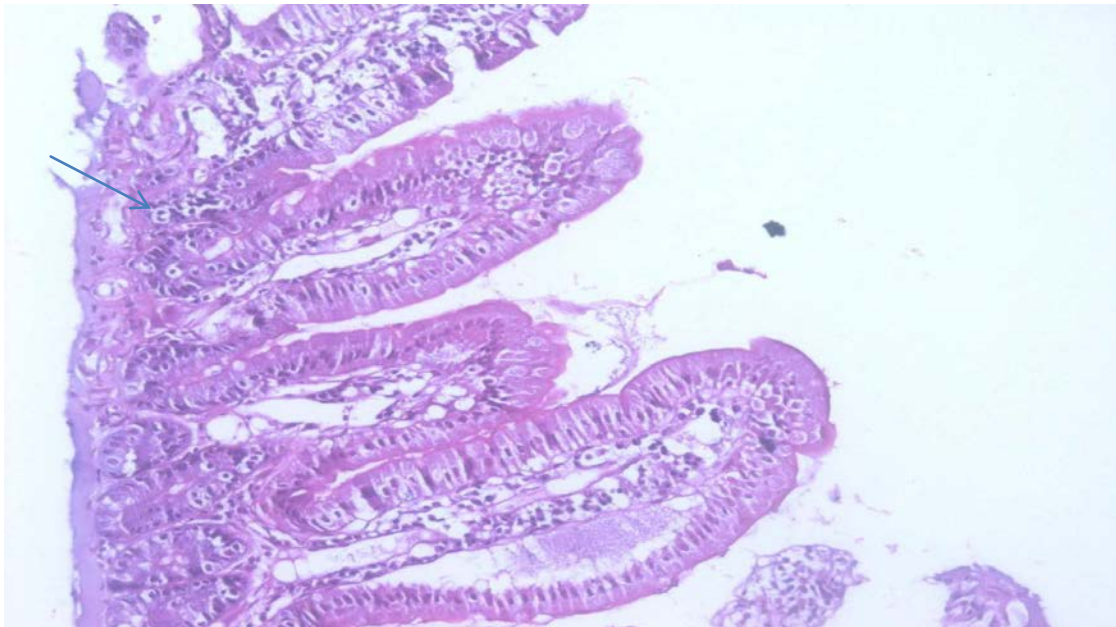
noted. However, it is not generally required for routine diagnosis of the organism (Aly et al., 2013).

The present study, showed a high significant difference between control and all treated groups. Best results were

observed when metronidazole was combined with either monolaurine or lactobacillus. Vegetative forms in the intestine and oocysts/gm stool were markedly reduced compared to the group receiving metronidazole alone.



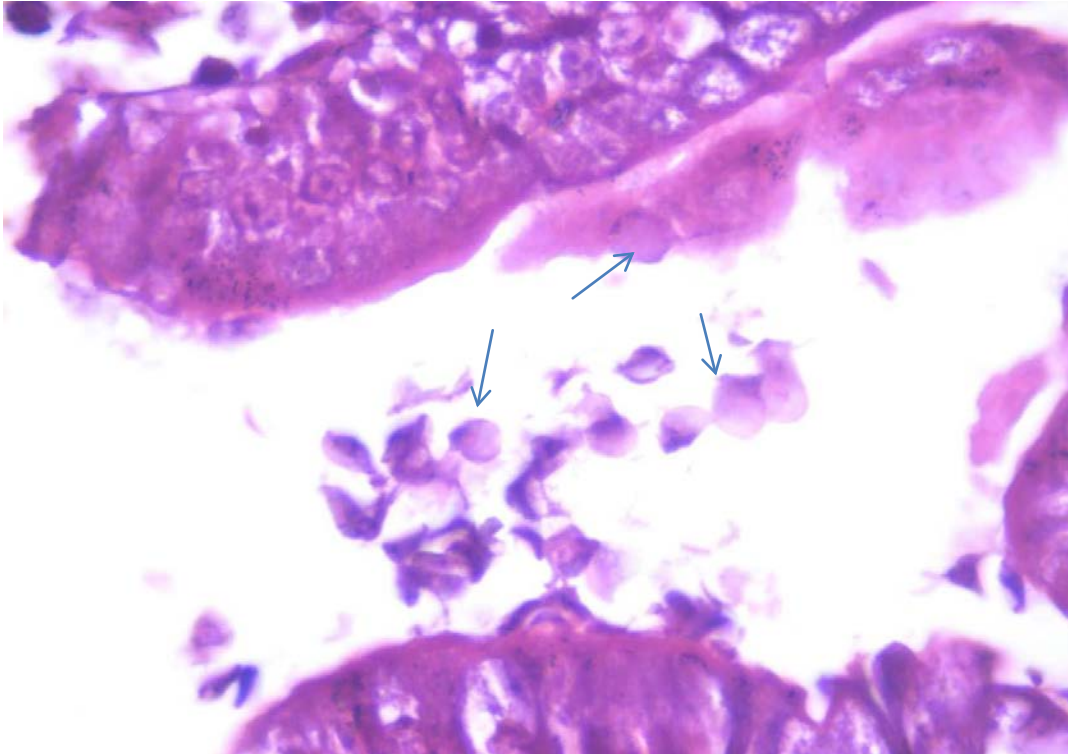
**Figure 5.** Monolaurine treated group intestine showing only moderate inflammation (arrow) with normal villi . No *Blastocystis*, H&Ex200.



**Figure 6.** Monolaurine + Metronidazole treated group intestine showing normal villi. No *Blastocystis* only foci of mild inflammation (as in treated group ). H&E x200.

Promising results were obtained when monolaurine or lactobacillus were given alone, compared to metronidazole. The study results are in accordance with

Choi et al. (2011), who found that *Saccharomyces boulardii* probiotics or metronidazole has potential beneficial effects on *B. hominis* infection (symptoms and



**Figure 7.** Monolaurine + Metronidazole treated group intestine showing normal villi. No *Blastocystis*. Only foci of moderate inflammation.

presence of parasites). The percentage of reduction in the number of *Blastocystis* cysts and trophozoites after treatment with *lauric acid* may be explained by its immunostimulatory effect through its ability to provoke lymphocyte proliferation and stimulation of T-cells proliferation via regulation of IL-2 production, a lymphokine necessary for T-cells proliferation (Helmy, 2010).

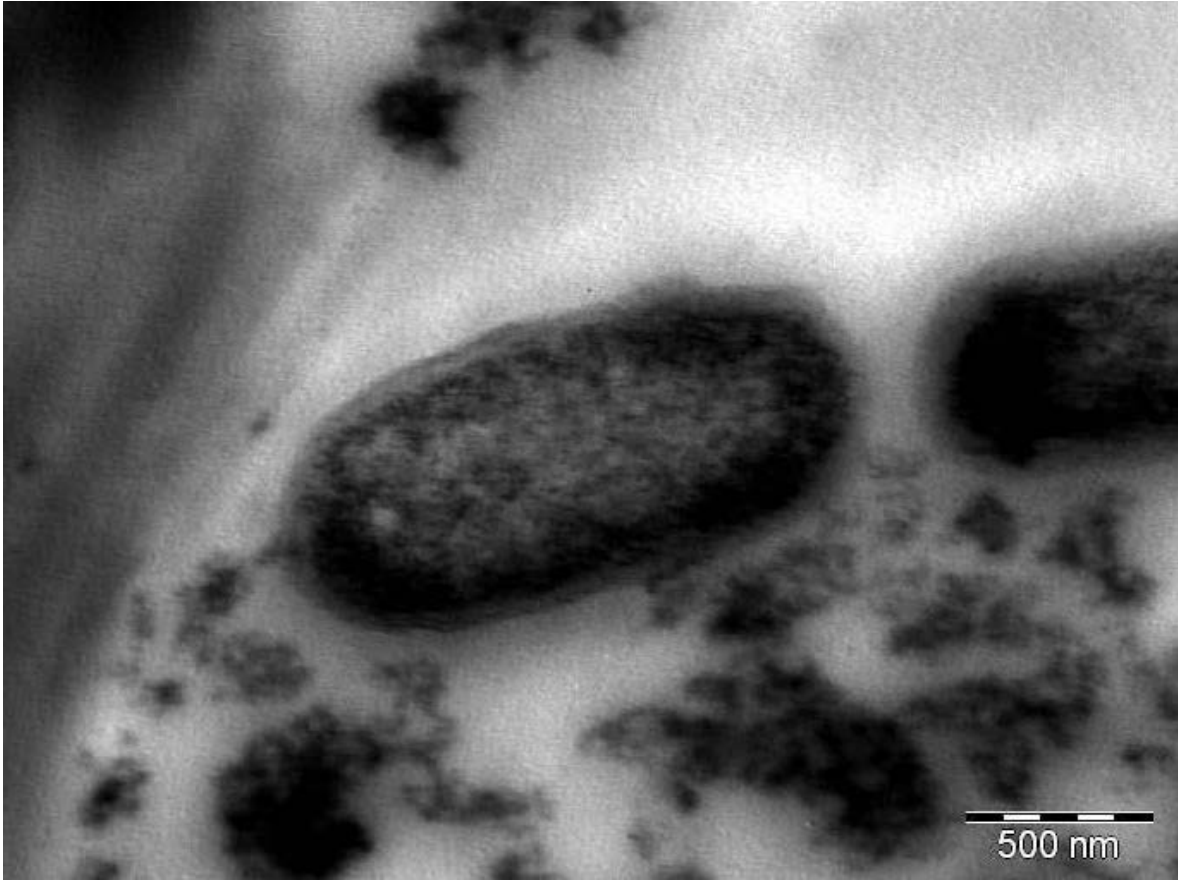
In the present study, the combined administration of metronidazole and *lauric acid* reported very good evidences of cure when compared to the results obtained following administration of the two drugs separately. This can be explained by a potential synergistic effect as each of the two drugs has a different mechanism of action. Similar results were obtained when *lauric acid* given alone or combined with metronidazole on experimental giardiasis. Rayan et al. (2007), reported that the anti-giardial activity of *lauric acid* was comparable to that of metronidazole.

In our study, the effect of lactobacillus was evaluated on both vegetative forms and oocyst/gm stool. The effect was more promising when combination with metronidazole was used. These results are in accordance with Amer et al. (2007), who found that the combined therapy resulted in a reduction rate of 99.32 and 98.69% in both cysts and vegetative form of *Giardia* spp. Histopathological examination of the infected control

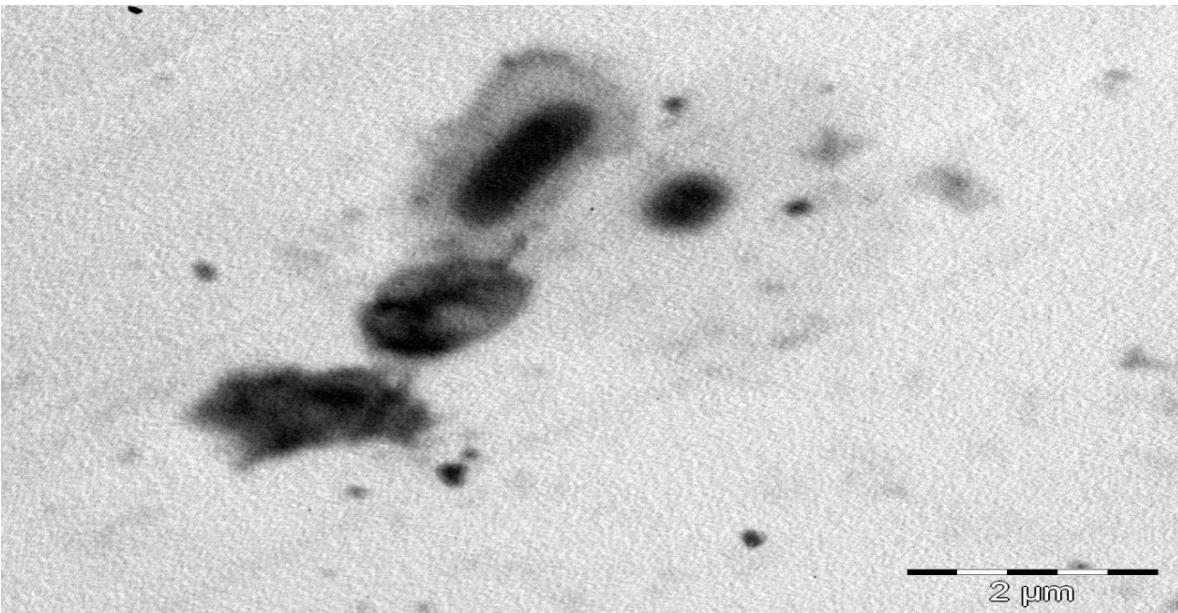
group revealed profound effect on the structure of the intestinal mucosa. This effect was in the form of villous shortening and atrophy, with infiltration of lamina propria with inflammatory cells. Additionally, *B. hominis* vegetative forms were detected in the intestinal lumen and in-between the villi.

In the current study, histopathological examination of intestinal sections from the infected groups treated with metronidazole, *lauric acid* (monolaurine) and lactobacillus, revealed an improvement in the form of normal villi, with mild to no inflammation and absence of *Blastocystis* at the intestinal surface. These results agree with those of Amer et al. (2007) and Aly et al. (2013) on their work on experimental giardiasis, who found that treatment with Metronidazole, *lauric acid* and Lactobacillus revealed an improvement in the form of partial healing of intestinal mucosa mild shortening and thickening of the villi, with few *Giardia* trophozoites were detected in the lumen. *Lauric acid* appeared to have a better ameliorating effect on the histopathology of the intestinal wall than Metronidazole.

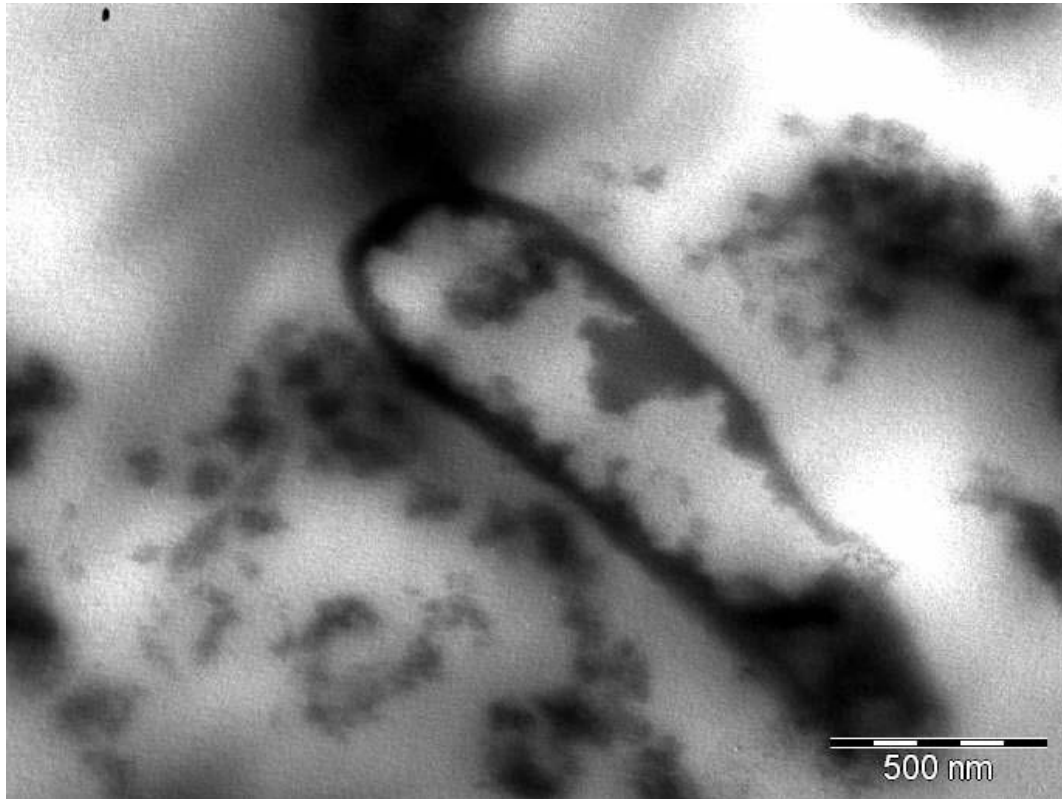
In our study, metronidazole showed normal villi with no inflammation and no *Blastocystis*. Monolaurine showed only moderate inflammation with normal villi and no *blastocystis* were detected. On the other hand, lactobacillus alone showed few deformed *Blastocystis* combined therapy of Metronidazole with either of the two



**Figure 8.** Control ultrastructure of *B. hominis*. TEM showing *B. hominis* cell displaying normal morphology and DNA chromatin seen as a crescentic band of electron opaque material mass mitochondrion like organelles are seen (X28000) control.



**Figure 9.** *Blastocystis* cell treated with metronidazole (200 µg/ml) showing shrinking of the cytoplasm and filamentous layer on surface and apoptotic change ( X8.9000).



**Figure 10.** *Blastocystis* cell treated with metronidazole (200 µg/ml) showing programmed cell death with apoptotic features. Nuclear chromatin produced clumps along the periphery. Large cytoplasmic vacuoles appeared empty. Formation of cytoplasmic bleb starting autolysis. (X8.9000).

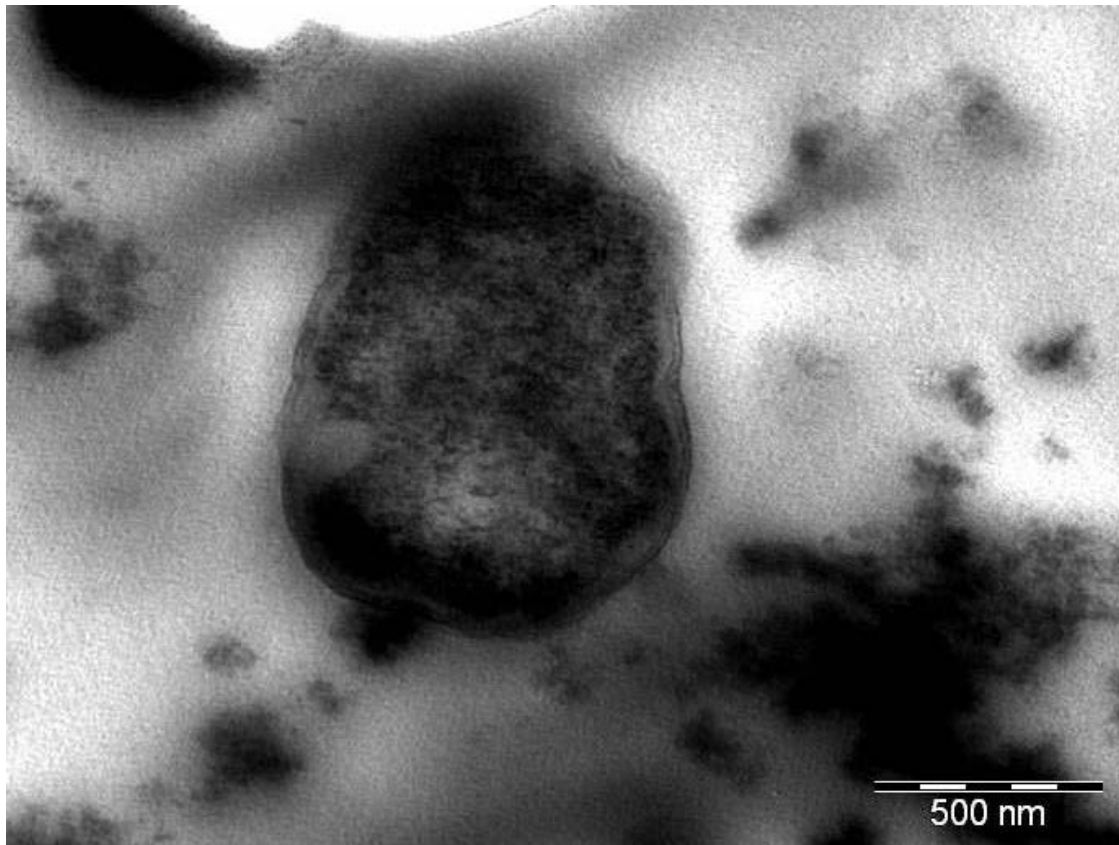
drugs showed normal intestinal villi, with no *Blastocystis*. El-Gayar and Soliman (2011), found that Quillaja soponaria showed remarkable improvement of histopathological findings; the mucosa was infiltrated with few inflammatory cells and submucosa was free from inflammation in addition to absence of *Blastocystis* cells. Lactoferrin treated group showed some deformed *Blastocystis* veg. forms. In agreement with the present results regarding the histopathological changes following Metronidazole treatment, Amer et al. (2007) reported partial healing of intestinal villi after Metronidazole treatment.

In the present study, the effect, lactobacillus and monolaurine was evaluated by the in-vitro growth of *B. hominis*. Different concentrations of lactobacillus (1000 and 2000 µg/ml) were incubated with *B. hominis* isolates in culture media at 37°C at different time intervals (1/2, 1 and 2 h). The treatment period at least 1 h was employed as previous standardized studies had shown that this time period is necessary to trigger the cytotoxic response in these parasites (Stenze and Bonham, 1996). At a concentration of 1000 µg/ml and after ½ an hour incubation, lactobacillus showed a reduction in the cells/ml (29.4) compared to 46.5 and 19.5 when metronidazole was called ½ an hour after incubation in

this study, lactobacillus at 2000 µg/ml showed highly significant reduction, in the number of concentration of *Blastocystis* after 1 h incubation after 2 h incubation rapid death of the parasite was detected. The effect of monolaurine on *Blastocystis* isolates in culture in a concentration of 2000 µg/ml showed 100% reduction in *Blastocystis* with no viable cells in culture even after incubation for ½ an hour metronidazole is the most frequently prescribed antibiotic (Tan, 2008).

In the present study, the reduction when metronidazole was added to *Blastocystis* culture in a dose of 120 mg/ml, was 54.9%, while when a dose of 200 mg/ml of the same drug was added to *Blastocystis* culture after incubation for 2 h, no viable cells were detected. These results are in accordance with Coyle et al. (2012) who, although considering metronidazole being the first line treatment for *Blastocystis*, stated that the success of eradicating the parasite with this drug has been reported to be anywhere between 0 and 100%. This variation in treatment response suggests the existence of resistant subtypes of the parasite (Mirza and Tan, 2012). The unresponsive patients are perhaps infected with resistant subtypes (Mirza et al., 2011).

Transmission electron microscopic studies are *Blastocystis* cells displayed key morphological features of



**Figure 11.** Ultrastructure of *B. hominis*. TEM showing *Blastocystis* cell after exposure to 2000 µg/ml lacteol fort (lactobacillus LB) showing shrinking of cytoplasm and distortion of cell at one pole (X 36000).

shrinkage of the cytoplasm and filamentous layers on the surface with apoptotic changes when *Blastocystis* cells were treated with metronidazole (Figure 2a) (200 µg/ml), in addition to programmed cell death with apoptotic features (Figure 2b). The results are in accordance with those obtained by Hassan et al. (2010) who observed similar findings. After exposure of *B. hominis* to lactobacillus 2000 µg/ml, TEM showed shrinkage of cytoplasm and distortion of cell at one pole (Figure 4).

Previous work by Hassan et al. (2010) proved that the *in-vitro* effects of *lauric acid* on *Blastocystis* cells include dose dependent apoptotic changes followed by cell lysis compared to the standard drug, metronidazole.

## Conclusion

In summary, a variety of drug treatment options are available for *Blastocystis* infections. Metronidazole appears to be the most effective drug for *Blastocystis* chemotherapy despite some evidence for treatment failure. The development of new therapeutic options to counter antimicrobial resistance requires the use of high-throughput screening tools. This study shows that natural products (example, monolaurine and lactobacillus),

can offer an alternative therapy to be used in place, concurrently with conventional antimicrobials. Monolaurine and lactobacillus proved to be useful as herbal consolidates for *B. hominis* therapy. Further studies are recommended on a larger number of isolates with relation to clinical manifestations. Molecular typing should be performed to further explain the difference in drug efficacy on different isolates.

## Conflict of Interests

The authors have not declared any conflict of interests.

## REFERENCES

- Alfellani MA, Taner-Mulla D, Jacob AS, Imeede CA, Yoshikawa H, Stensvold CR, Clark CG (2013). Genetic diversity of *Blastocystis* in livestock and zoo animals. *Protist*, 164(4):497-509.
- Aly MM, Shalaby MA, Artia SS, E-Sayed SH, Mahmoud SS (2013). Therapeutic effect of *lauric acid*, a medium chain saturated fatty acid. On *Giardia lamblia* in experimentally infected hamsters. *PUJ* 6(1):89-98.
- Amer NM, Mahmoud SS, Helmy A, Hammam O (2007). The role of probiotics in controlling *Giardia intestinalis* in experimental animals. *New Egypt J. Med.* 37:13-23.



- Blagg W, Schlogel E, Mansour NS, Khaled GJ (1955). A new concentration technique for the demonstration of protozoa and helminth's eggs in faeces. *Am. J. Tropical Med. Hygiene* 1: 23-28.
- Boorom KF, Smith H, Nimri L, Viscogliosi E, Spanakos G, Parkar U, Jones MS (2008). Oh my aching gut: Irritable bowel syndrome, Blastocystis, and asymptomatic infection. *Parasitol. Vectors* 1(1):40.
- Choi CH, Jo SY, Park HJ, Chang SK, Byeon JS, Myung SJ (2011). A randomized, double-blind, placebo-controlled multicenter trial of *Saccharomyces boulardii* in irritable bowel syndrome: Effect on quality of life. *J. Clin. Gastroenterol Press*.
- Coyle CM, Varschehese J, Weiss L, Tanowitz HB (2012). *Blastocystis* to treat or not to treat. *Clin. Infectious Diseases* 54(1):105-110.
- Diaz E, Mondragon J, Ramirez E, Bernal R (2003). Epidemiology and control of intestinal parasites with nitazoxanide in children in Mexico. *Am. J. Tropical Med. Hygiene* 68(4):384-385.
- EI-Gayar E, Soliman RH (2011). *In vitro* and *in vivo* effects of quillaha saponasia on *Blastocystis hominis* isolates. *Parasitol. United J.* 4(1):101.
- Fenoglia-Preiser CM, Noftinger AE, stemmermann GN (2008). Gastrointestinal pathology. An Atlas and Text. 3<sup>rd</sup> ed. USA: Walters Kluwer, Lippincott Williams and Wilkins P 834.
- Grimaud JA, Druget M, Peyrol S, Chevalier D (1980). Light and electron microscope study. *J. Histochem. Cytol.* 28:1145-1151.
- Hassan SI, Moussa HME, Fahmy ZH Mohamed AH (2010). *In vitro* effect of medium-chain saturated fatty acid (Dodecanoic acid) on *Blastocystis* Spp. *Int. J. Infect Disease* 14:584.
- Jenkins B, Holsten S, Bengmark S, Martindale R (2005). Probiotics: A practical review of their role in specific clinical scenarios. *Nutr. Clin. Pract.* 20(2):262-270.
- John A, Catanzaro ND, Green L (1997). Microbial ecology and probiotics in human medicine. *Altern. Med. Rev.* 2(4):296-305.
- Kelesidis T, Pothoulakis C (2012). Efficacy and safety of the probiotic *Saccharomyces boulardii* for the prevention and therapy of gastrointestinal disorders. *Ther. Adv. Gastroenterol.* 5:111-125.
- Kulik RA, Falavigna DL, Nishi L, Araujo SM (2008). *Blastocystis* sp. and other intestinal parasites in hemodialysis patients. *Braz. J. Infect Disease* 12:338-341.
- Kumiawan A, Karyadi T, Dwintasari SW, Sari IP, Yuniastuti E, Djauzi S, Smith HV (2009). Intestinal parasitic infections in HIV/AIDS patients presenting with diarrhea in Jakarta, Indonesia. *Transactions Royal Society Tropical Med. Hygiene* 103: 892-898.
- Mirza H, Tan KS (2012). Clinical Aspects of Blastocystis Infections: Advancements amidst controversies. In: Mehlhorn H, Tan KS, Yoshikawa H, editors. *Blastocystis: Pathogen or Passenger?* Verlag Springer Berlin Heidelberg pp. 65-84.
- Mirza H, Teo JD, Upcroft J, Tan KS (2011). A rapid, high throughput viability assay for *Blastocystis* spp. reveals metronidazole resistance and extensive subtype dependent variations in drug susceptibilities. *Antimicrob. Agents Chemother.* 55(2):637-648.
- Parkar U, Traub RJ, Kumar S, Mungthin M, Vitali S, Leelayoova S, Thompson RCA (2007). Direct characterization of Blastocystis from faeces by PCR and evidence of zoonotic potential. *Parasitology* 134(03):359-367.
- Poirier P, Wawrzyniak I, Vivares CP, Delbac F, El Alaoui H (2012). New insights into *Blastocystis* spp.: A potential link with irritable bowel syndrome. *Plos Pathog.* 8(3):e1002545.
- Rayan H, Ismail OE, Gayar E (2007). Prevalence and clinical features of *D. fragilis* infection in patients suspected to have intestinal parasitic infection. *J. Egypt Soc Parasitol.* 37:599-608.
- Rosignol JF, Kabil SM, Said M, Samir H, Younis AM (2005). Effect of nitazoxanide in persistent diarrhea and enteritis associated with *Blastocystis hominis*. *Clin. Gastroenterol. Hepatol.* 3:987-991.
- Scanlan PD (2012). *Blastocystis*: past pitfalls and future perspectives. *Trends Parasitol.* 28:327-334.
- Sekar U, Shanthi (2013). *Blastocystis*: Consensus of treatment and controversies. *Tropical Parasitol.* 3(1):35-39.
- Stenzel DJ, Boreham PF (1996). *Blastocystis hominis* revisited. *Clin. Microbiol. Rev.* 9:563-584.
- Tan KS (2008). New insights on classification, identification, and clinical relevance of *Blastocystis* spp. *Clin. Microbiol. Rev.* 21:639-665.
- Tan KS, Mirza H, Teo JD, Wu B, Macary PA (2010). Current views on the clinical relevance of *Blastocystis* spp. *Current infectious disease reports* 12:28-35.
- Tasova Y, Sahin B, Koltas S, Paydas S (2000). Clinical significance and frequency of *Blastocystis hominis* in Turkish patients with hematological malignancy. *Acta Med. Okayama* 54:133-136.
- Termmathurapoj S, Leelayoova S, Aimpun P, Thathaisong U, Nimmanon T, Taamasri P, Mungthin M (2004). The usefulness of short-term *in vitro* cultivation for the detection and molecular study of *Blastocystis hominis* in stool specimens. *Parasitol. Res.* 93(6):445-447.
- Travers AM, Florent I, Kohl L, Grellier P (2011). Probiotics for the control of parasites: An overview. *J. Parasitol. Res.* 2011 Article ID 610769.
- Zierdt CH (1988). *Blastocystis hominis*, a long misunderstood intestinal parasite. *Parasitol. Today* 4:15-17.
- Zierdt CH (1991). *Blastocystis hominis*-past and future. *Clin. Microbiol. Rev.* 4(1):61-79.
- Zierdt CH, Donnelly CT, Muller J, Constantopoulos G (1988). Biochemical and ultra structural study of *B. hominis*. *J. Clin. Microbiol.* 26(5):965-970.



# African Journal of Pharmacy and Pharmacology

**MEDICAL**

Related Journals Published by Academic Journals

- *Journal of Medicinal Plant Research*
- *African Journal of Pharmacy and Pharmacology*
- *Journal of Dentistry and Oral Hygiene*
- *International Journal of Nursing and Midwifery*
- *Journal of Parasitology and Vector Biology*
- *Journal of Pharmacognosy and Phytotherapy*
- *Journal of Toxicology and Environmental Health Sciences*

**academicJournals**